

Summarised from Journal of Clinical Periodontology, Volume 49, issue 3 (March 2022), 280-291

Editors: Phoebus Madianos & Andreas Stavropoulos, EFP scientific affairs committee

Rapporteurs:

Tim Thomassen, Patrick Rijkschroeff, and Georgios Loukas
with Dr. Monique Danser and Prof. Bruno Loos

Affiliation:

EFP-affiliated programme in periodontology at ACTA (Academic Center for Dentistry Amsterdam), Amsterdam, Netherlands

study

Does hyaluronic acid promote alveolar-ridge preservation?

Authors:

Celien Eeckhout, Julie Ackerman, Maarten Glibert, and Jan Cosyn

Background

Proper dental implant placement and good soft-tissue aesthetics may be hampered by a narrow alveolar ridge. The alveolar ridge preservation (ARP) procedure is an important technique for clinicians to use to limit the dimensional changes of the alveolar process after tooth extraction.

The extraction socket can be filled with bone grafts, and this has proven effective. However, predictable approaches to enhancing the soft-tissue barrier that protects underlying biomaterials and to accelerating wound healing are still lacking. Recent systematic reviews have shown that ARP may limit alveolar bone resorption by up to 50% of what is observed after traditional socket healing.

To attain a fully preserved alveolar ridge after tooth extraction, further techniques related to soft-tissue wound healing need to be explored. One potential wound-healing accelerator is high-molecular-weight hyaluronic acid (HA). In vitro, HA can enhance the proliferation and migration of human fibroblasts.

Therefore, the adjunctive use of HA gel in an ARP procedure could play a role in soft-tissue healing and the enhancement of the soft-tissue barrier on biomaterials in the healing socket.

Aim

The aim of this study was to compare the administration of a hyaluronic acid (HA) gel to no gel administration following ARP, in terms of changes in soft-tissue wound dimensions over a four-month post-operative healing period.

Materials & methods

- This randomised clinical trial included systemically and periodontally healthy, non-smoking patients who needed tooth extraction and ARP in the aesthetic zone.
- Teeth were extracted without flap elevation or with minimal reflection of the interdental papilla to avoid soft-tissue damage. Following wound debridement and rinsing, the alveolar socket was filled with Bio-Oss collagen up to the lingual bone crest and sealed with Mucograft Seal and Seralon 6/0 sutures.
- In the test group, 0.8% HA gel (Gengigel Forte) was applied, and patients were instructed to self-apply HA gel onto the wound three times per day for seven days.
- Systemic amoxicillin (2g) was prescribed for all subjects to be taken one hour before the procedure and a similar dose was to be taken after the intervention for the next four days. Anti-inflammatory medication (ibuprofen 600mg) was taken one hour before the surgery and in the postoperative period when needed.
- The primary outcome was the change in wound dimensions in the early healing phase. Wound dimensions were measured immediately after the procedure and compared with those measured one and three weeks post-operatively.
- A secondary outcome was changes in buccal and lingual bone dimensions (height and width) using small-field, low-dose CBCT images immediately after the procedure and four months post-operatively.
- Complications (alveolitis, alveolar osteitis, socket wound-healing score), patient-related outcome measures (total number of analgesics, post-operative pain), and patient compliance were also measured.

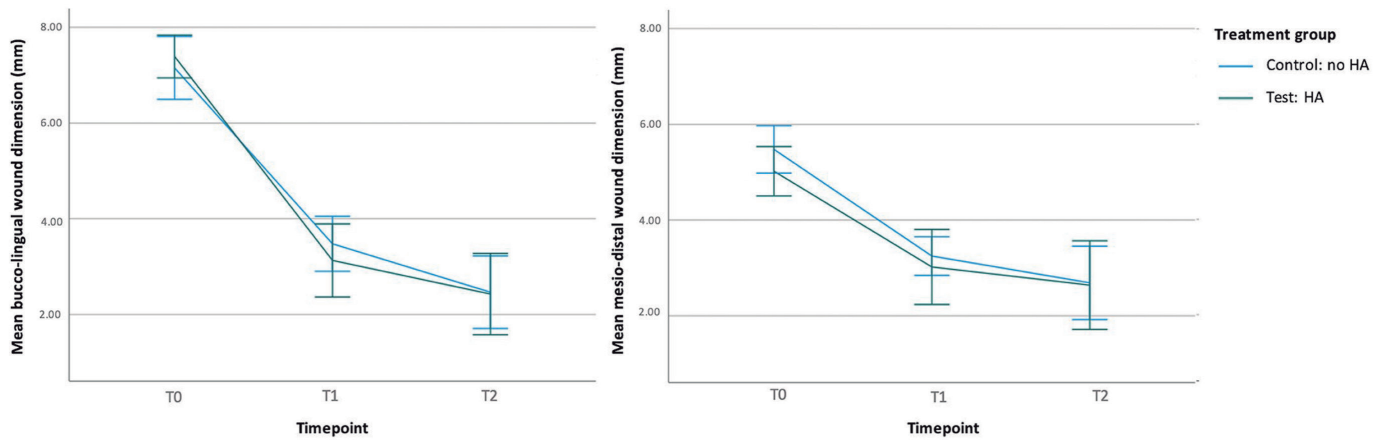


Figure: Buccolingual and mesiodistal wound dimensions at T0 (immediately post-operation), T1 (one week), and T2 (three weeks). Estimated marginal means and 95% CIs are shown.

Results

- This study was completed on 38 subjects, which included 18 participants in the test group and 20 participants in the control group.
- The biggest reductions in wound dimensions were observed in the buccolingual aspect one week post-operatively compared to baseline (4.26mm test group, 3.63mm control group). The wound-dimension reductions were not significantly different between the HA-gel group and the control group.
- More horizontal bone-level reductions were observed for the test group (level 1: 3.55mm; level 2: 2.56mm) compared to the control group (level 1: 1.92mm; level 2: 1.35mm, with $p = 0.025$ and $p = 0.016$ respectively).
- There were no significant differences observed for post-operative complications, patient-related outcome measures, and patient compliance.

Limitations

- It is unclear whether at baseline both groups were comparable, since no statistical analysis of the baseline characteristics was presented.
- The high viscosity of the HA gel used resulted in poor tissue adhesion which could have an impact on its effectiveness.
- In the control group, no gel was applied. The use of a placebo gel in the control group would have been preferable from a methodological point of view. The authors explain that its preparation could not be supported by the pharmaceutical industry.
- The study was underpowered regarding the secondary outcomes, therefore reported differences between test and control group on horizontal bone-level reductions need to be interpreted with caution.
- At the patient level, the test group showed non-significant trends for more postoperative pain, more oedema, alveolitis, and a higher number of analgesics used post-operatively.

Conclusions & impact

- The application of HA gel on the healing wound after ARP procedure did not accelerate wound resolution and did not prevent some horizontal bone loss.
- There are no statistically significant differences between ARP sites treated with or without HA gel in relation to other soft-tissue changes or to patient-reported and clinical outcomes.
- In daily practice, professional and self-applied HA gel three times a day for seven days on top of a collagen matrix (seal) after an ARP procedure does not seem to improve the wound healing and does not prevent some loss of buccal and lingual bone.



JCP Digest 99 is a summary of 'A randomized controlled trial evaluating hyaluronic acid gel as wound healing agent in alveolar ridge preservation'. J Clin Periodontol. 49(3), 280-291. DOI: 10.1111/jcpe.13589



<https://www.onlinelibrary.wiley.com/doi/10.1111/jcpe.13589>



Access through EFP members' page log-in: <http://efp.org/members/jcp.php>